



## Case Report

## Adrenal Insufficiency Associated with Cholestatic Jaundice: A Case Report



Wei-Cheng Lee<sup>a, c</sup>, Shou-Chuan Shih<sup>a, c</sup>, Horng-Yuan Wang<sup>a, c</sup>, Chien-Liang Wu<sup>b, c</sup>,  
Shih-Yi Lee<sup>b, c\*</sup>, Hui-Chun Ku<sup>d, 1</sup>

<sup>a</sup> Division of Gastroenterology, Department of Internal Medicine, MacKay Memorial Hospital, Taipei, Taiwan, <sup>b</sup> Division of Pulmonary and Critical Care Medicine, Department of Internal Medicine, MacKay Memorial Hospital, Taipei, Taiwan, <sup>c</sup> Mackay Junior College of Medicine, Nursing, and Management, Taiwan, <sup>d</sup> Institute of Pharmacology, College of Medicine, National Taiwan University, Taiwan

## ARTICLE INFO

## Article history:

Received 30 December 2016

Received in revised form

29 April 2017

Accepted 24 May 2017

Available online 22 June 2017

## Keywords:

cholestasis,  
adrenal insufficiency

## SUMMARY

Various disorders result in jaundice. Adrenal insufficiency is a rare cause of neonatal cholestasis, which is reversible with prompt glucocorticoid administration. Cholestasis caused by adrenal insufficiency has not been reported in adult patients. We present a case of a 65-year-old male with jaundice and without hepatitis A, B, or C. Endoscopic retrograde cholangiopancreatography showed a patent biliary tract. Liver pathology revealed no malignancy but showed bile stasis compatible with cholestatic hepatitis. The patient's jaundice persisted for 7 weeks, and at the same time, adrenal insufficiency was diagnosed. Adrenal insufficiency was recovered with glucocorticoid therapy, and the jaundice was cured.

Copyright © 2017, Taiwan Society of Geriatric Emergency & Critical Care Medicine. Published by Elsevier Taiwan LLC. This is an open access article under the CC BY-NC-ND license (<http://creativecommons.org/licenses/by-nc-nd/4.0/>).

## 1. Introduction

The coexistence of cholestasis and adrenal insufficiency is clinically rare. Congenital hypopituitarism is a recognized cause of neonatal hepatitis<sup>1–4</sup>. Neonatal cholestasis associated with isolated adrenal insufficiency is another cause<sup>5</sup>. Glucocorticoid treatment can prevent liver failure in neonates with congenital adrenal hyporesponsiveness<sup>2</sup>. In animal models, adrenalectomized rodents have shown cholangiocyte proliferation and a significant decrease in bile output<sup>6,7</sup>, similar to the rodents subjected to bile duct ligation<sup>7</sup>. Although the mechanism remains unclear, we believe that adrenal function may play a major role in cholestatic patients.

To the best of our knowledge, cholestasis caused by adrenal insufficiency seems to be limited to the early infantile period and is observed in animal models<sup>1–7</sup>. We report the case of a 65-year-old male presenting with intrahepatic cholestasis and relative adrenal insufficiency, which were cured by glucocorticoid therapy.

## 2. Case report

A 65-year-old male under regular hemodialysis was admitted to our ward due to pneumonia. While pneumonia was cured with piperacillin/tazobactam, he developed jaundice. Although we stopped the administration of all agents that potentiate hepatotoxicity, his total/direct bilirubin levels increased from 3.5/2.3 to 11.0/7.1 mg/dL (normal value: 0.3–1.2/0.1–0.5 mg/dL) and glutamate oxaloacetate transaminase (GOT)/glutamic-pyruvic transaminase (GPT) levels increased from 90/48 to 189/83 IU/L (normal value: 15–41/14–40 IU/L) in the subsequent four weeks.

The patient's alkaline phosphatase level was 1176 IU/L (normal value: 38–126 IU/L) and  $\gamma$ -glutamyl transpeptidase level was 983 IU/L (normal value: 7.5–50 IU/L). Abdominal sonography revealed gallbladder stones but showed no evidence of cholecystitis or bile duct dilatation. Computed tomography showed normal bile and intra-hepatic ducts. Endoscopic retrograde cholangiopancreatography revealed neither filling defect of bile ducts nor common bile duct dilatation. Hepatitis B surface antigen, hepatitis C antibody, hepatitis A IgM antibody, antinuclear antibody, cytomegalovirus antibody, Epstein–Barr virus capsid antibody, antimitochondrial antibody, and antismooth muscle antibody were negative. Liver biopsy revealed mild-to-moderate bile stasis in the hepatocytes and bile canaliculi. Iron stain, hepatitis B surface antigen and hepatitis core antigen were negative.

\* Correspondence to: Shi-Yi Lee, Division of Pulmonary and Critical Care Medicine, Department of Internal Medicine, MacKay Memorial Hospital, No. 92, Sec. 2, Zhongshan N. Rd., 10449, Taiwan, ROC. Fax: +886 225433642.

E-mail address: [leesy5538@yahoo.com.tw](mailto:leesy5538@yahoo.com.tw) (S.-Y. Lee).

<sup>1</sup> Co-first author.

The patient had generalized malaise, weight loss (from 57 to 49 kg in a month), hyperpigmentation, and intermittent hypotension (systolic and diastolic blood pressure of 85–90 and 55–60 mmHg, respectively). Nevertheless, the heart rate, respiratory rate, and body temperature were within normal limits. The adrenal function test showed elevated adrenocorticotropic hormone levels of 161.45 pg/mL (normal value: 10–70 pg/mL), with normal cortisol levels of 14.19 pg/dL (normal value: 4.75–23.27 pg/mL). Adrenal insufficiency was confirmed with cortisol levels of 12.1 pg/dL at 0 min, 16.55 pg/dL at 30 min, and 17.83 pg/dL at 60 min after cosyntropin stimulation. Following the administration of cortisol acetate at 37.5 mg per day, the blood pressure returned to normal, body weight recovered to 53 kg, and total bilirubin levels declined to 3.69 mg/dL in 2 weeks (Fig. 1). At the same time, the liver function improved (GOT: 54 IU/L; GPT: 58 IU/L; alkaline phosphatase: 818 IU/L;  $\gamma$ -glutamyl transpeptidase: 284 IU/L). He had no discomfort and his vital signs were normal without hypotension or bradycardia. Consequently, he was discharged. Twelve months after discharge, his condition remained stable. We gradually tapered the dose of cortisol acetate from 25 mg once daily in the morning and 12.5 mg once at night to 25 mg once daily in this period. The latest adrenal function on March 31, 2017 was within the normal range (adrenocorticotropic hormone: 33.73 pg/mL; cortisol: 23.50 pg/mL); his liver function and bilirubin levels were normal (total bilirubin: 0.5 mg/dL; GOT: 19 IU/L; GPT: 13 IU/L). We tapered the cortisol acetate dose to 12.5 mg once daily and will continue regular follow up.

### 3. Discussion

Cholestasis linked to isolated adrenal insufficiency is clinically rare and represents 1% of neonatal cholestasis<sup>5</sup>. However, hepatic manifestations of adrenal insufficiency beyond infancy include hypertransaminasemia but not cholestasis<sup>8,9</sup>. We report a unique case of an adult with adrenal insufficiency associated with intrahepatic cholestasis.

Prompt diagnosis and treatment for intrahepatic cholestasis caused by adrenal insufficiency in adults are crucial, not only

because delayed treatment may cause cirrhosis<sup>4,10</sup> but also because the misuse of steroids may cause intrahepatic cholestasis<sup>11</sup>. Drugs may cause prolonged cholestasis<sup>12–14</sup>; however, exacerbating jaundice persisted after stopping the administration of suspected agents such as piperacillin/tazobactam. Thus, it seems unlikely that cholestasis is linked to the administration of drugs<sup>15</sup>. Sepsis may inhibit bilirubin metabolism and cause cholestasis<sup>16,17</sup>. However, clinical presentations suggested that jaundice occurred after pneumonia had been cured and there were no signs of sepsis. Steroids could also reverse hepatitis virus-induced protracted jaundice<sup>18,19</sup>. However, the viral markers in this case could exclude virus-induced jaundice. Therefore, the resolution of cholestasis by hydrocortisone replacement therapy in this case may suggest a causal link between cortisol deficiency and the development of adult cholestasis.

The mechanism linking cholestasis with adrenal insufficiency remains unclear, but investigations based on adrenalectomized rodents have revealed cholangiocyte proliferation and bile flow reduction, similar to the observations in rodents subjected to bile duct ligation<sup>6,7</sup>. Cholangiocyte proliferation and bile flow reduction caused by bile duct ligation could be reversed by cortisol<sup>7</sup>. Effects of cortisol on the ducts in this study were comparable with those in other studies; cortisol therapy recovered bile secretion in adrenalectomized rodents<sup>20,21</sup>. In addition, elevated hepatic bile acids in surgically induced extra-hepatic biliary obstruction could cause deleterious effects on the structure and function of adrenocorticytes, adrenal gland atrophy, and adrenal insufficiency<sup>22–24</sup>. These data suggest the presence of a vicious cycle between adrenal insufficiency and cholestasis.

Our case may reveal the vicious cycle between adrenal insufficiency and cholestasis. The patient's jaundice persisted for 7 weeks and could be only dramatically regressed by glucocorticoid therapy after the diagnosis of adrenal insufficiency was confirmed, suggesting that cortisol reversed the adrenal insufficiency and stopped the course of cholestasis. The possible causes of jaundice could be sepsis-associated liver injuries, drugs, or even viral infections that have been excluded by the clinical course and blood tests. In our case, adrenal gland suppression may be related to poor clinical

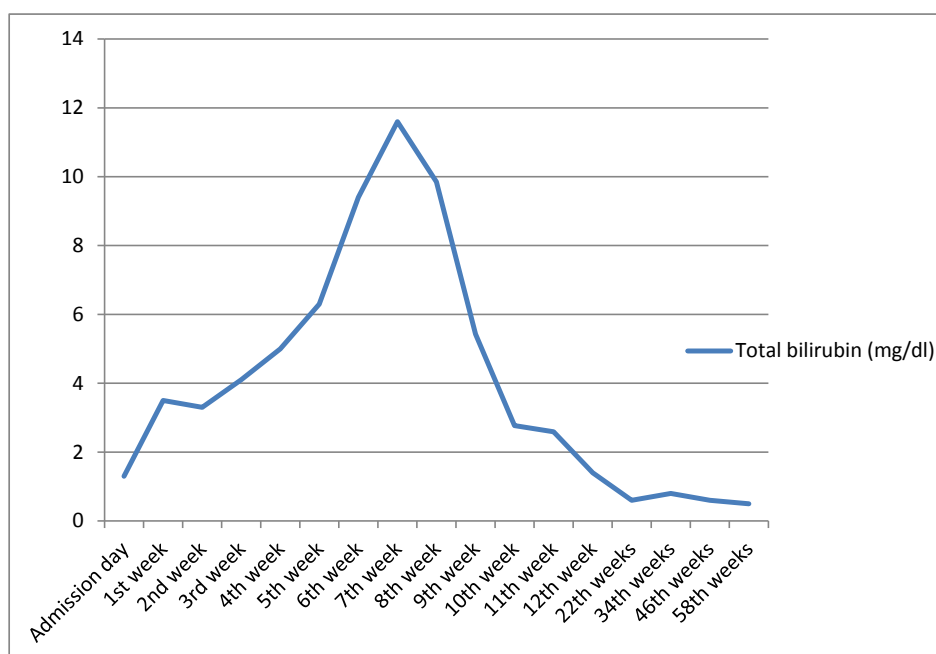


Fig. 1. Clinical course of serum bilirubin (mg/dL) levels of the patient.

conditions, including regular hemodialysis, recent recovery from pneumonia, and persistent jaundice.

In conclusion, to the best of our knowledge, intrahepatic cholestasis caused by adrenal insufficiency has not been reported in adults. This report highlights a unique case of an adult with adrenal insufficiency showing intrahepatic cholestasis reversed by glucocorticoid therapy.

### Conflict of interest

None.

### References

- Gonc EN, Kandemir N, Andiran N, et al. Cholestatic hepatitis as a result of severe cortisol deficiency in early infancy: report of two cases and review of literature. *Turk J Pediatr.* 2006;48:376–379.
- Cheung M, Bansal S, Aw MM, et al. Liver failure in a neonate with congenital adrenal hyporesponsiveness. *Eur J Pediatr.* 2003;162:558.
- Lee WS, Lum LC, Harun F. Addisonian-like crisis in congenital hypopituitarism and cholestatic jaundice. *Med J Malays.* 2003;58:279–281.
- Spray CH, McKiernan P, Waldron KE, et al. Investigation and outcome of neonatal hepatitis in infants with hypopituitarism. *Acta Paediatr.* 2000;89:951–954.
- Al-Hussaini A, Almutairi A, Mursi A, et al. Isolated cortisol deficiency: a rare cause of neonatal cholestasis. *Saudi J Gastroenterol.* 2012;18:339–341.
- Telkka A, An K. Bile flow in adrenalectomized rats. *Acta Endocrinol (Copenh).* 1962;41:57–60.
- Quinn M, Ueno Y, Pae HY, et al. Suppression of the HPA axis during extrahepatic biliary obstruction induces cholangiocyte proliferation in the rat. *Am J Physiol Gastrointest Liver Physiol.* 2012;302:G182–G193.
- Nguyen KD, Sundaram V, Ayoub WS. Atypical causes of cholestasis. *World J Gastroenterol.* 2014;20:9418–9426.
- Gurakuqi GC, Stadlbauer V, Stepan V, et al. Addison's disease as a rare cause of chronically elevated liver enzymes. *Z Gastroenterol.* 2006;44:179–183.
- Balistreri WF, Bezerra JA, Jansen P, et al. Intrahepatic cholestasis: summary of an American Association for the Study of Liver Diseases single-topic conference. *Hepatology.* 2005;42:222–235.
- Parizek A, Duskova M, Vitek L, et al. The role of steroid hormones in the development of intrahepatic cholestasis of pregnancy. *Physiol Res.* 2015;64(Suppl 2):S203–S209.
- Degott C, Feldmann G, Larrey D, et al. Drug-induced prolonged cholestasis in adults: a histological semiquantitative study demonstrating progressive ductopenia. *Hepatology.* 1992;15:244–251.
- Koklu S, Koksas AS, Asil M, et al. Probable sulbactam/ampicillin-associated prolonged cholestasis. *Ann Pharmacother.* 2004;38:2055–2058.
- Chamouard P, Walter P, Baumann R, et al. Prolonged cholestasis associated with short-term use of celecoxib. *Gastroenterol Clin Biol.* 2005;29:1286–1288.
- Naranjo CA, Busto U, Sellers EM, et al. A method for estimating the probability of adverse drug reactions. *Clin Pharmacol Ther.* 1981;30:239–245.
- Bolder U, Ton-Nu HT, Scheingart CD, et al. Hepatocyte transport of bile acids and organic anions in endotoxemic rats: impaired uptake and secretion. *Gastroenterology.* 1997;112:214–225.
- Roelofsens H, van der Veere CN, Ottenhoff R, et al. Decreased bilirubin transport in the perfused liver of endotoxemic rats. *Gastroenterology.* 1994;107:1075–1084.
- Yoon EL, Yim HJ, Kim SY, et al. Clinical courses after administration of oral corticosteroids in patients with severely cholestatic acute hepatitis A; three cases. *Korean J Hepatol.* 2010;16:329–333.
- Pullukçu H, Kahraman H, Yamazhan T, et al. Use of steroids for prolonged cholestasis secondary to acute hepatitis A. *J Microbiol Infect Dis.* 2014;4:162–164.
- Bauman Jr JW, Chang BS, Hall FR. The effects of adrenalectomy and hypophysectomy on bile flow in the rat. *Acta Endocrinol (Copenh).* 1966;52:404–408.
- Settimi A. Increase of biliary flux by cortisone in guinea pigs. *Boll Soc Ital Biol Sper.* 1955;31:679–681.
- McNeilly AD, Macfarlane DP, O'Flaherty E, et al. Bile acids modulate glucocorticoid metabolism and the hypothalamic-pituitary-adrenal axis in obstructive jaundice. *J Hepatol.* 2010;52:705–711.
- Soliman HM, Abd El-Haleem MR, El Tarhouny SA. Histomorphometrical and electron microscopic study of adrenocorticocytes following surgically induced extrahepatic biliary obstruction in adult female albino rats. *Folia Biol (Praha).* 2015;61:14–25.
- Swain MG, Patchev V, Vergalla J, et al. Suppression of hypothalamic-pituitary-adrenal axis responsiveness to stress in a rat model of acute cholestasis. *J Clin Invest.* 1993;91:1903–1908.